

Thyroid incidentaloma

Thyroid incidentaloma is a thyroid swelling found during imaging study for parts other than the thyroid gland.

- **If ultrasound, CT scan or MRI show thyroid incidentaloma; then:**

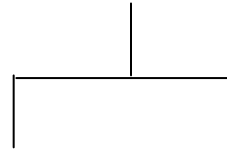
If it is less than 1.5cm in size & the ultrasound, CT scan & MRI show it to be benign, then observe the swelling.

If the incidentaloma is greater than 1.5cm & there is history or radiation exposure, & the ultrasound, CT scan or MRI. Suspect cancer, then do ultrasound guided FNA cytology.

If FNA cytology shows benign results, then observe if FNA cytology shows malignancy or suspect malignance, then operate on (total or near total thyroidectomy).

Thyroid incidentaloma

On ultrasound, CT scan or MRI



If it is greater than 1.5cm & the ultrasound, CT scan or MRI show malignancy or suspect malignancy & or there is history of radiation exposure

If it is less than 1.5cm & the ultrasound, CT scan or MRI show it benign

↓
Observe



Ultrasound guide FNA cytology



Malignancy or
Suspect malignancy



Operate



Benign



Observe